

Continuum Technique

by Stephen Typaldos, DO, Fort Worth, Texas
The Manual Medical Center of Fort Worth

Introduction

Continuum technique is a soft tissue manipulative approach used in the treatment of acute and chronic musculoskeletal pain and dysfunction. It is based on the premise that injuries can occur in tissues, 'transition zones', and correction of the distortion caused by the injury will result in an improvement in both subjective and

objective findings. Transition zones are found between different tissue types and are a CONTINUUM from one of the tissue types to another. It is thought that during an injury the percentages of certain tissue components of each 'subzone' become 'shifted'. This results in pain, tenderness, tightness, decreased motion of the affected area and

swelling. Continuum Technique is designed to reverse this process by 'shifting' the continuum back into its original configuration. Once this occurs, there is normally a dramatic and instantaneous improvement in both range of motion and pain. Continuum Technique is particularly useful in the emergency room setting in which ankle and knee sprains and cervical and lumbar strains are treated on a daily basis. Drawings of proposed 'shifting' continuum of a ligament-bone transition zone are shown in Figures 1 and 2.

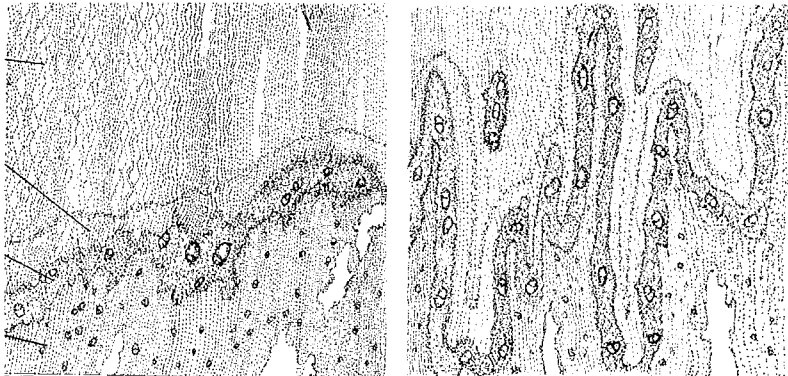


Figure 1

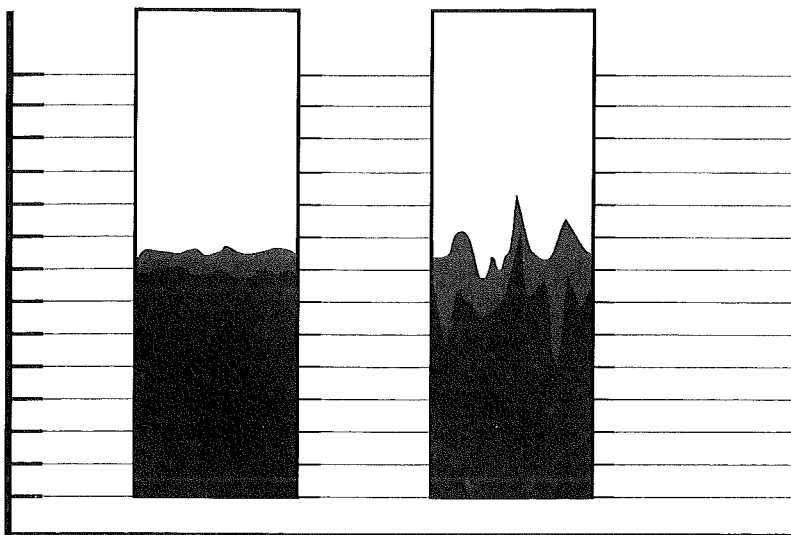


Figure 2

Clinical Applications of Continuum Theory

A common example of 'shifting' continuum can be seen in ankle sprains. In the transition zone between ligament and bone are four subzones. During the injury itself, bony components from the zone of lamellar bone are 'pulled' into the mineralized fibrocartilage zone. At the same time mineralized fibrocartilage components are 'pulled' into the unmineralized fibrocartilage zone, and unmineralized fibrocartilage components are 'pulled' into the ligamentous zone. The net effect of this is that the entire transitional zone has become 'shifted' into the direction of the ligament. This results in a ligament that is now not only stiffer than it was prior to the injury but is also functionally shorter. Continuum

→

Technique utilizes pressure in the OPPOSITE direction, which forces the continuum to 'shift' back into the direction of its pre-injury state.

The amount of force used in Continuum Technique to 'shift' the continuum back into its pre-injury state is equal to the force that caused the injury in the first place. The difference is that the direction of the force applied is OPPOSITE and is much more SPECIFIC in that it is applied only to the resultant distortion rather than to the injured area as a whole. Although the patient may complain of the entire ankle hurting, this is not anatomically correct. Only certain specific distortions have occurred and once they are corrected the patient may then be pain-free, regardless of how much pain or swelling he or she had upon entering the emergency department.

The treatment itself is normally painful. This is because the forces that caused the injury were significant and thus the treatment forces used to correct it also need to be significant. But the pain induced by the treatment is temporary and once the distortion is corrected the severe pain and tenderness are gone despite how much force is then applied to the injured area. In most ankle sprains there are normally two to five continuum distortions that need to be corrected. Other acute injuries may involve only one. If only a portion of the distortions are corrected there will be only a partial improvement, and although this may still obtain a superior result compared to standard treatments, it is not the dramatic and complete result that is normally anticipated and hoped for with Continuum Technique.

Continuum Technique works on an all-or-none principle. Either the continuum distortion resolved or it did not. There is no in-between. If an objective and dramatic result does not occur, then a complete

reevaluation should be done. Failure to respond suggests either the diagnosis was incorrect (i.e., a fracture was missed) or the technique itself was improperly applied. The most common reason for improper technique is hesitancy of the physician to use adequate force. With experience this is easily overcome.

The actual physical act of Continuum Technique involves applying firm pressure with the physician's thumb to the area of distorted continuum. The distortion itself is located by palpation of the distortion and by the amount of pain induced by the palpatory process. Firm pressure is applied into the direction

*"Continuum
Technique
works
on an
all-or-none
principle."*

of maximum pain. The patient may describe the pain as being intolerable, or more graphically "like a hot poker". The physician will feel it to be something like 'a bubble of gel in a small button'. If the patient expresses that the pain is "not that bad", then the direction and force of intensity should be changed until the pain is maximized again. The pressure should be constant and gradually increased until 'resolution'. When this occurs both physician and patient are immediately aware of it. The patient experiences an immediate and dramatic reduction in pain and tightness, and the physician feels as if the 'button has slipped into

the button hole'. The resolution process can also be described by patients as a 'release'. The 'release' of the distorted continuum occurs over a period of one to five seconds with two being the average. Once the 'release' is complete, that distortion is considered 'corrected', and the other distortions are treated if they are present. When all the distortions have been corrected the treatment is completed. Follow-up is advised in a day or two to recheck for any residual distortions.

Continuum distortions should not be confused with other types of fascial distortions. They are not 'triggerbands' which have a completely different etiology and treatment, and are the subject of the accompanying paper *Triggerband Technique*. In addition, they are not 'triggerpoints' which are compared with continuum distortions in *Introducing the Fascial Distortion Model*. The differentiation of continuum distortions from these other fascial distortions is clinically relevant because the treatment modality selected should be based upon the anatomical findings encountered. Failure to appreciate this point will greatly decrease the results of any modalities used. The presentation of other distortions in the same patient at the same time occurs rather commonly. Triggerbands often occur in acute ankle, knee, cervical and lumbar sprains. They should be treated if they are present. In chronic pain, triggerbands should be treated first before Continuum Technique is utilized. This is because adhesions have formed which are holding the injury in its 'shifted state'. Once the triggerband is corrected then the continuum distortion can be successfully treated.

Continuum distortions commonly occur at the origin or insertion of ligaments or tendons with bone.

Because of this they can be found in the neck, back, ribs, elbows, knees or other locations that have tendons or ligaments. The treatment of all of them is essentially the same—that is, to guide the injured area into the direction of pain and to correct the distortion. The illustrations in Figures 3-6 show some of the most common sites of continuum distortions that are seen in the emergency room patient. Treatment of ankle sprains are then discussed in the following section. These are perhaps the most rewarding to treat since they often respond so dramatically. But just as each patient is different so is each injury, and modifications are necessary for optimal results. As with any treatment modality the diagnosis is paramount, and contradictions should be reviewed before usage (see Triggerband Technique paper). Almost all patients will accept a painful treatment if it is effective, which fortunately when using Continuum Technique occurs most of the time.

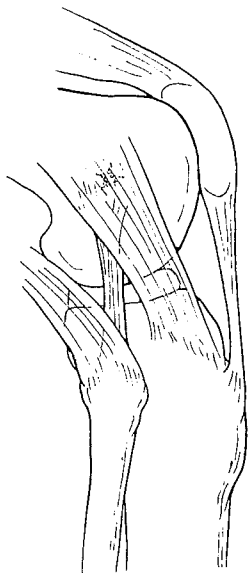


Figure 3

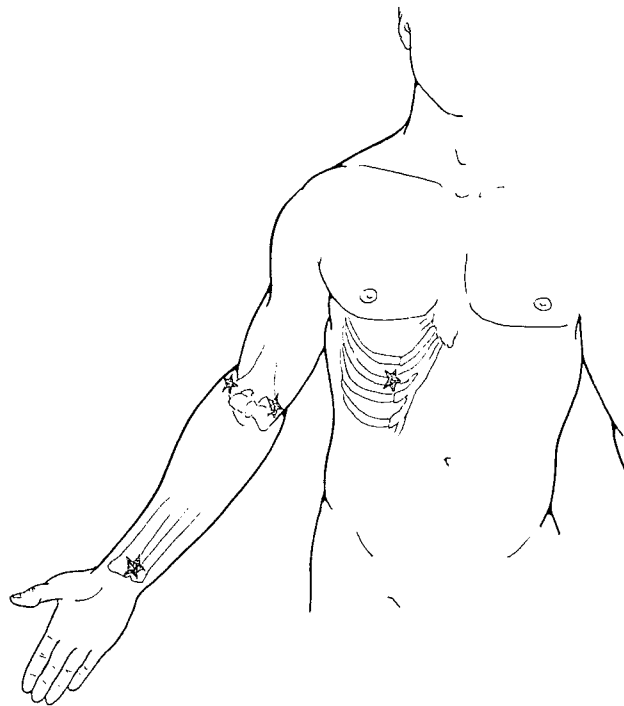


Figure 4

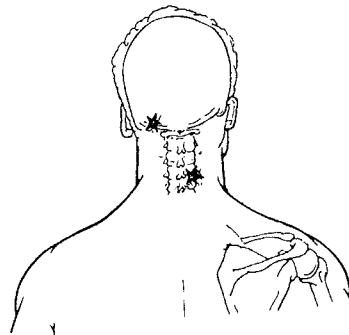


Figure 5

Treatment of the Acutely Sprained Ankle

Sprained ankles are perhaps one of the most common extremity injuries seen in the emergency room setting. The usual treatment of these consists of rest, ice, elevation, splinting and anti-inflammatory and analgesic medications. This treatment regimen typically results in gradual subjective improvement and takes days or weeks until most patients are able to walk

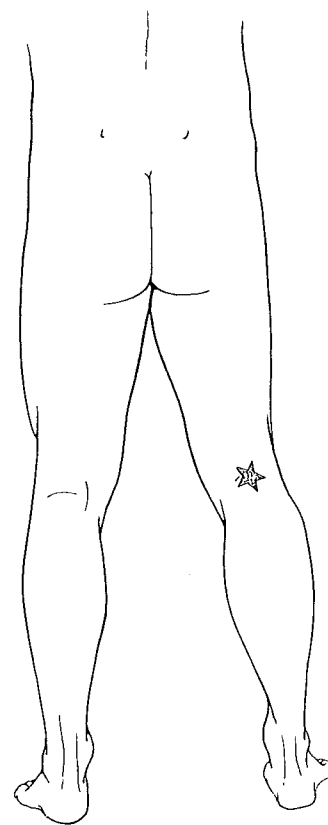


Figure 6



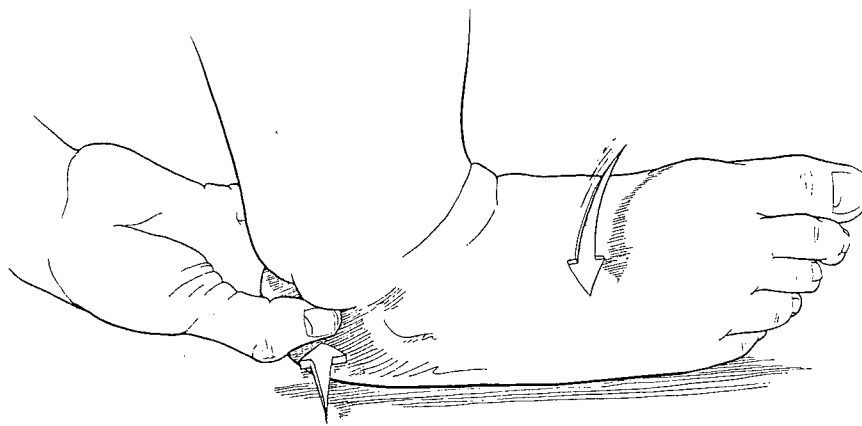


Figure 7a

limp-free. Some patients continue to have residual pain even months later. In the fascial distortion model the sprained ankle is viewed as consisting of alterations of the bone-ligament transition zone. Once the distortion is corrected then optimally there should be normal range of motion and no pain. Fortunately, in the emergency room setting this dramatic result is typical. Any result that is not dramatic should make the physician suspicious of an underlying fracture.

In the chronically injured ankle, adhesions have formed and Triggerband Technique must be employed before using Continuum Technique. These patients normally complain of the pain radiating from the ankle into the knee, foot or hip. To successfully treat them it is necessary

to correct all of those fascial distortions. Treating only the ankle will result in failure. Normally several treatments are needed for the chronically sprained ankle, and after the third or fourth visit thrusting manipulation of the joint is advised. Acutely sprained ankles rarely need high velocity manipulation, and often respond poorly to this treatment modality.

Typical Steps in the Treatment of the Acutely Sprained Ankle

1) Physical examination—record passive and active range of motion and check for ligament instability and vascular compromise.

2) X-ray the ankle to rule out fracture.

3) Have the patient point to the 'spot' of most intense pain.

4) Explain to the patient that you are going to examine the injury more carefully and that he or she can expect a temporary increase in discomfort.

5) Gently rotate the ankle into the position in which it was injured, normally done by inverting the foot. Palpate the area indicated by the patient and feel for the continuum distortion. Gently apply pressure and gradually increase the force until resolution. Please refer to **Figures 7a and 7b.**

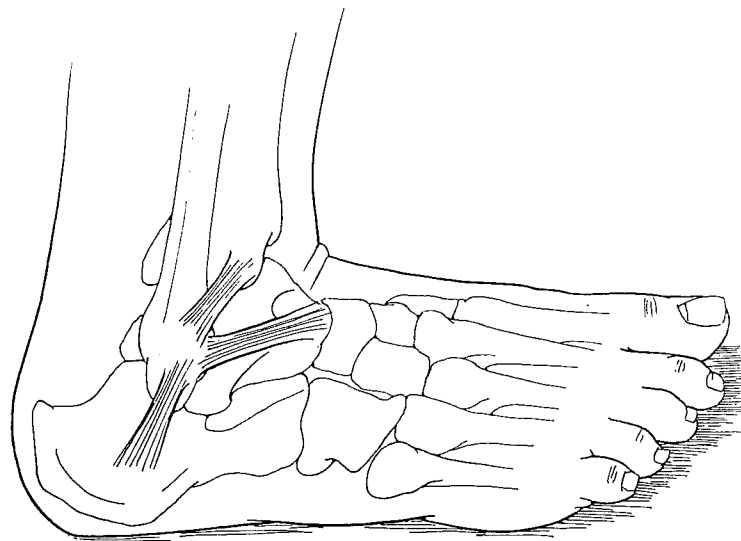


Figure 7b

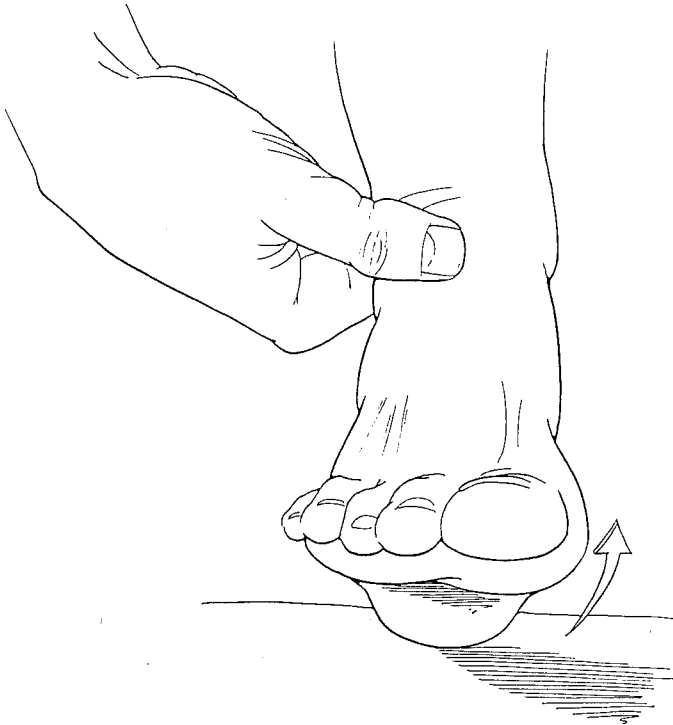


Figure 8a

6) After the first distortion is corrected, recheck the range of motion and have the patient palpate the area just corrected. This will demonstrate to him or her that improvement has occurred.

7) Again gently guide the ankle into a position that elicits pain. Ask the patient to point to the most painful spot, and feel for the distortion. **Figures 8a and 8b** show the most common anterior ankle distortions. Correct it in the same manner, recheck the range of motion and ask once more where it hurts. Repeat the sequence until the patient reports only a diffuse sensation of generalized tenderness or no pain.

8) Ask the patient to stand and point to where the ankle still hurts. While

the patient is standing, correct the distortion in the same manner as previously described. Repeat this step until the patient can stand with little or no pain.

9) Next have the patient walk and identify what movement induces pain. Then hold the ankle in that position and correct the distortion.

10) Once the range of motion has been restored and the patient has had either a dramatic reduction in pain or is pain free, he or she can then be discharged from the emergency room. Ice is encouraged and splints and medication are considered to be optional. Follow-up with their own doctor is advised in 24-48 hours. □

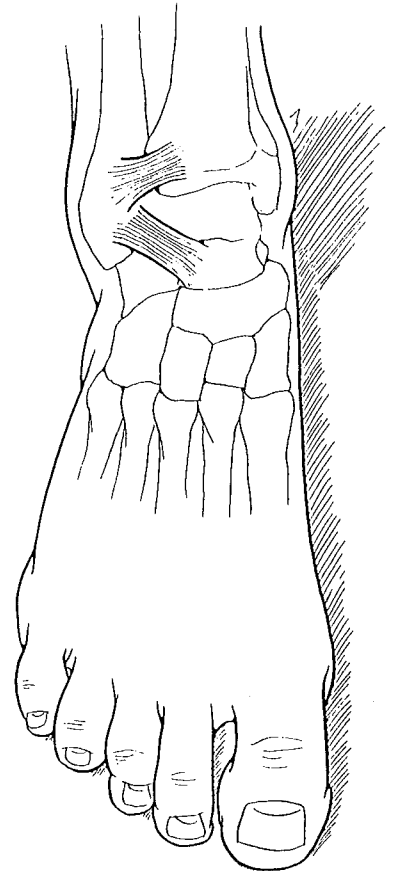


Figure 8b

Key Words

*continuum distortion
ankle sprain
transition zone*